CHAPTER 14 – MUSCULOSKELETAL SYSTEM

First Nations and Inuit Health Branch (FNIHB) Pediatric Clinical Practice Guidelines for Nurses in Primary Care.
The content of this chapter has been revised August 2010.

Table of Contents

For detailed information on the clinical presentation, assessment and management of other musculoskeletal problems occurring in children, *see Chapter 7, "Musculoskeletal System" in the Adult Clinical Practice Guidelines.*

ASSESSMENT OF THE MUSCULOSKELETAL SYSTEM

HISTORY OF PRESENT ILLNESS

History varies with age and type of condition.

GENERAL[1]

The following characteristics of each symptom should be elicited and explored:

- Onset (sudden or gradual, associated with injury or strain)
- Acuity or chronicity
- Chronology
- Location and character
- Presence of radiation and course
- Quality, severity and extent
- Timing (frequency, duration, intermittent or constant)
- Deformity (such as swelling, inflammation, contracture, unusual positioning or appearance)
- Precipitating and aggravating factors
- Relieving factors
- Associated symptoms
- Effects on daily activities and play
- Previous diagnosis of similar episodes
- Previous treatments
- Efficacy of previous treatments
- Ask about fever
- Assess and monitor discomfort using age-appropriate pain intensity instruments such as the *"Wong-Baker FACES Pain Scale"* (available at: www.partnersagainstpain.com/printouts/A7012AS6b.pdf), the *"Numeric Rating Scale"* (available at: www.partnersagainstpain.com/printouts/A7012AS7.pdf), the *"CRIES Pain Scale"* (available at: http://pain.about.com/od/testingdiagnosis/ig/paint-scales/Cries-Scale.htm) or the *"Comfort Scale"* (available at: www.partnersagainstpain.com/printouts/Patient-Comfort-Assessement-Guide.pdf)

BONES AND JOINTS

- Pain (younger children may not localize pain well)
- Nocturnal awakening because of pain
- Swelling
- Redness
- Heat
- Stiffness
- Time of day when symptoms are most bothersome
- Relation of symptoms to movement
- Limitation of movement
- Change of gait or play activity (for example, limp)
- Deformity
- Extra-articular findings (for example, rash)
- Trauma (obtain accurate description of exact mechanism of injury)

MUSCLES

- Pain
- Weakness
- Wasting
- History of previous injuries and treatment received

NEUROVASCULAR STRUCTURES

- Paresthesia
- Paresis
- Paralysis
- Skin: rash or signs of physical abuse (for example, bruises, welts, cigarette burns)
- Lymph node enlargement[2]

FUNCTIONAL ASSESSMENT

- Inability or refusal to use limb or to bear weight (especially in a young child)
- Self-care deficits (for example, in bathing, dressing, toileting, grooming)
- Mobility and use of mobility aids

MEDICAL HISTORY (SPECIFIC TO MUSCULOSKELETAL SYSTEM)

- Recent infection, such as an upper respiratory tract infection, meningitis or a soft tissue infection
- Recent immunization (specifically if vaccine was administered in affected limb)
- Previous trauma (to bones, joints, ligaments)
- Arthritis (juvenile rheumatoid arthritis)
- Recent immobilization of an extremity
- Medications (for example, steroids)[3]
- Obesity
- Congenital problem with orthopedic involvement[3]
- Pregnancy and birth history such as breech, shoulder presentation, multiple births, oligohydramnios, asphyxia at birth or maternal alcohol or substance abuse[3]
- Development history such as reaching developmental milestone at appropriate age[3]

FAMILY HISTORY (SPECIFIC TO MUSCULOSKELETAL SYSTEM)

- Rheumatoid arthritis
- Diabetes mellitus (associated with osteoarthritis in adults)
- Lupus erythematosus

PERSONAL AND SOCIAL HISTORY (SPECIFIC TO MUSCULOSKELETAL SYSTEM)

- Absenteeism from school (multiple days)
- Sports activities (for example, contact sports involving repetitive motion)
- Risk behaviours for injuries, especially in adolescents (for example, snowmobiling, illicit drug use, alcohol abuse [specifically drinking and driving])
- Dietary calcium and vitamin D intake
- Smoking
- Exercise habits
- Traditional activities such as hunting and fishing

PHYSICAL EXAMINATION

Although the musculoskeletal and neurologic systems are discussed separately in this set of guidelines, they are usually examined together *(see the section "Assessment of the Central Nervous System" in Chapter 15, "Central Nervous System")*.

VITAL SIGNS

- Temperature may be elevated in inflammatory or infectious disease
- Tachycardia from pain or shock if major trauma is involved
- Blood pressure normal, unless child is in shock from major trauma

INSPECTION

Although the inspection is perhaps the most important part of the exam, a systematic approach includes the following steps:

- **I**nspection
- **P**alpation
- **R**ange of motion
- **E**xamine the extremities: assess the joint above and below
- **N**eurologic exam
- **S**pecial examination of involved joint(s)

Inspection should be initiated from general to specific:

- Apparent state of health
- Child may look acutely ill because of an infectious or inflammatory process
- Appearance of comfort or distress
- Distress (related to pain) is often observed if there is an infectious, inflammatory or fracture-related cause
- Significant trauma to an extremity may result in shock-like appearance
- Colour (for example, flushed, pale)
- Nutritional status (obese or emaciated)

Observe:

- Mobility
- Gait and posture, as patient walks into the room
- Presence of limp or unwillingness to bear weight
- Symmetric limb deformity such as a valgus: deviation or outward angulation of the distal segment of a bone or joint (a > < shape of the two legs is observed); or a varus: deviation or inward angulation of the distal segment of a bone or joint (a < > shape of the two legs is observed)[1]
- Determine ability to perform activities of daily living (for example, sitting, standing, walking, dressing, playing)
- Compare corresponding paired joints and bones for the following characteristics

Swelling:

- Around joint area (may indicate arthritis: chronic, acute or infectious)
- Over bony area (may indicate trauma, fracture or tumour)
- In soft tissue (may indicate trauma or infection)

Redness:

- Implies inflammatory process or infection
- Note any induration and extent of redness
- Rash

PALPATION

- Location of tenderness
- Swelling and induration (for example, tissues feel tense, "boggy")
- Presence of heat implies inflammatory process or infection (if an area feels hot to the touch, compared to uninvolved joints or skin)
- Subcutaneous nodules
- Swelling around joints (may indicate joint effusion or infection)
- Crepitus may be palpable with joint movement or in soft tissue overlying bony fractures

- Range of motion of joints (active and passive)
- Resistance to or pain on movement of joint
- Degree of joint movement achieved
- Stability and integrity of ligaments
- Tendon function

RANGE OF MOTION

The normal values of joint motion are age related (for example, external hip rotation is greater in infancy). Assess bony limits of movements. Passive range of motion, where the examiner moves the joint, provides information on joint mobility and stability, as well as the limits of tendons and muscles that may be contracted. Active range of motion, where the child moves the joint, provides information about muscle and bony structures allowing functional movement.[3] Examine the child's gait and posture, preferably walking without shoes and undressed for observation of posture.

NEUROLOGIC AND VASCULAR FUNCTION

- Pallor
- Limb temperature (especially coolness)
- Peripheral pulses
- Paresthesia
- Paralysis
- Assess the neurologic status of the affected limb(s). *See "Assessment of the Central Nervous System" in Chapter 15, "Central Nervous System"*

SPECIAL EXAMINATION

Refer to the *"Musculoskeletal System"* section under *"Physical Examination of the Newborn" in Chapter 1, "Pediatric Health Assessment" for the Ortolani and Barlow maneuvers*.

The Galeazzi maneuver may be used to identify developmental dysplasia of the hip. It will be positive when knee heights are unequal. Place the child supine and flex the hip and knees, placing the sole of the feet on the table near the buttocks. Look for equality in the knee heights. This maneuver is not reliable in children with dislocatable but not dislocated hips or children with bilateral dislocation.[5]

The Trendelenburg sign is elicited when a child stands and raises one leg off the ground. If the pelvis (iliac crest) drops on the raised leg side, the sign is positive. It indicates a weak hip abductor muscle on the side that is bearing the weight.[5]

The Adams's test will detect asymmetry of the posterior chest wall on forward bending and allow for the evaluation of structural scoliosis.[5]

COMMON PROBLEMS OF THE MUSCULOSKELETAL SYSTEM

LIMB PAIN

Often presents as an alteration of activity or gait or an unwillingness to bear weight or use a limb.

The affected joint may not be the one the child complains about; for example, pain may be referred from disease of the hip joint to the knee, and the child presents with knee pain.

HISTORY

- Trauma: acute or subacute
- Infection (pain may be related to upper respiratory tract infection [URTI] or skin infection)
- Distress variable, from significant (as in septic arthritis) to mild (as in chronic juvenile rheumatoid arthritis, in which stiffness is predominant)
- Fever (high in cases of septic joints)
- Variable degree of limitation of activity (for example, child with septic joint or significant trauma is less likely to be able to bear weight)

PHYSICAL FINDINGS

Physical findings are variable, depending on the specific underlying cause. Look for:

- Fever or change in vital signs (distress may cause increase in heart and respiratory rates)
- Heat, redness, swelling, obvious deformity
- Decrease in mobility
- Bone tenderness

Always examine all joints in the affected limb, not just the one indicated by the child. Perform a general physical examination to look for signs of other illnesses (for example, rash with Henoch-Schönlein purpura or heart disease with rheumatic fever).

DIFFERENTIAL DIAGNOSIS

- Cellulitis (of the overlying areas only; no involvement of bones or joint spaces)
- Septic arthritis (this is an emergency situation)
- Transient viral arthritis
- Juvenile rheumatoid arthritis
- Transient toxic synovitis (commonly seen in the hip); related to previous URTI
- Osteomyelitis
- Trauma (for example, hemarthrosis)
- Post-immunization arthritis (especially after immunization for rubella)
- Bleeding disorder (for example, hemophilia)
- Henoch-Schönlein purpura (look for abdominal pain and rash)
- Sprain or strain
- Fracture
- Pulled elbow
- Slipped capital femoral epiphysis
- Legg-Calvé-Perthes disease
- Growing pains (diagnosis of exclusion)
- Rickets (know the community epidemiology in this case)
- Malignant lesion (for example, patient experiencing recurrent pain or awakening at night may indicate significant pathology)
- Rheumatic fever

The diagnosis of limb pain is difficult and should be undertaken with the help of a physician or advanced practice nurse. Septic arthritis and osteomyelitis can be life-threatening, as can fractures to large bones and joints.

DIAGNOSTIC TESTS

Discuss with a physician or nurse practitioner. Possible tests include complete blood count (CBC), erythrocyte sedimentation rate (ESR), blood culture and x-ray.

MANAGEMENT

Goals of Treatment

- Relieve pain, inflammation and fever (if present)
- Eradicate infection with appropriate antibiotics (if present)
- Minimize risk of further injury (for example, contractures)

Appropriate Consultation

Consult a physician if there is acute pain with significant compromise in function, if you are unsure of the diagnosis, if there is significant trauma or if there is a possibility of joint or bone infection.

Adjuvant Therapy

If the child appears acutely ill, if infection is suspected (for example, cellulitis, septic arthritis), or if there is significant trauma:

- Start IV therapy with normal saline and run at a rate sufficient to maintain hydration

For daily maintenance fluid requirements and signs of dehydration, *see "Fluid Management" in the section "General comments about fluid management" in Chapter 4, "Fluid management"*.

Nonpharmacologic Interventions

- Bed rest
- Immobilize extremity to prevent damage, ease pain

Pharmacologic Interventions

Antipyretic and analgesic for fever and pain:

ibuprofen (Advil, Motrin):

Children 6 months to 12 years: 5–10 mg/kg PO q6-8h prn; maximum 40 mg/kg/day

Children > 12 years: 200–400 mg q6-8h prn

Use lowest effective dose, shortest treatment duration; give with food

Ibuprofen also has anti-inflammatory effects

or

acetaminophen (Tylenol):

Infants and children < 12 years: 10–15 mg/kg per dose, PO q4-6h prn

Children and adolescents ≥ 12 years: 325–650 mg q4-6h; maximum 4 g/day

Acute inflammation of a joint in association with fever but no obvious cause for the inflammation should be treated as an infection (with the advice of a physician). While awaiting transfer, the physician may order antibiotics, such as the following:

cefazolin (Ancef), 25–100 mg/kg/day IV (maximum 6 g/day), divided q6-8h

or

cefuroxime (Zinacef), 75–150 mg/kg/day IV (maximum 6 g/day), divided q8h

Monitoring and Follow-Up

Monitoring and follow-up vary, depending on the diagnosis.

Referral

Most cases of acute limb pain require medevac. Cases of mild, non-acute limb pain can be referred electively to a physician or nurse practitioner for evaluation.

IN-TOEING

Inward pointing of toes. If mild, may resolve on its own; if extreme, treatment is required.

CAUSES

- *Metatarsus varus:* adduction of forefoot on hindfoot (lateral border of foot is curved instead of straight); presents in infancy
- *Internal tibial torsion:* in-turning of entire foot (medial twisting of tibia); presents in early childhood (9 months to 4 years)
- *Internal femoral anteversion:* in-turning of leg (medial twisting at hip); presents in early childhood

HISTORY

- May be associated with stumbling
- Sleeping with feet tucked underneath legs (tibial torsion)
- Sitting in the W-position, with knees together and feet spread laterally (femoral anteversion)

PHYSICAL FINDINGS

Metatarsus Varus

Forefoot is turned medially on the hindfoot. Ankle joint has normal dorsiflexion and plantar flexion.

Physiologic metatarsus varus can lead to adduction of forefoot past midline (no treatment needed).

Tibial Torsion

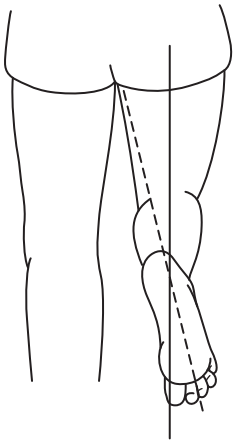

Measured by angle between foot and thigh with ankle and knee positioned at 90°. The foot normally rotates externally with age (about 2° at about 1 year of age; about 20° at 15 years of age). In tibial torsion, this angle is smaller.

Measuring Rotation in Femoral Anteversion

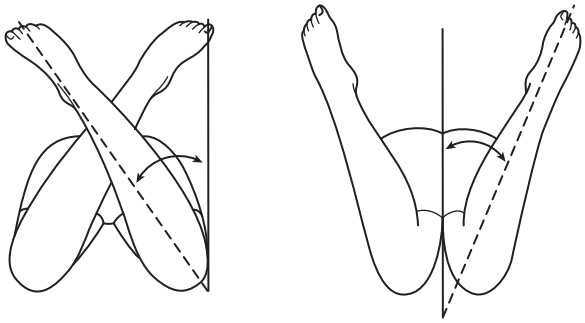

Decreased external rotation of the hip; if external rotation is less than 20°, in-toeing may result.

DIFFERENTIAL DIAGNOSIS

- More severe congenital deformity with clubfoot (rigid deformity of whole foot, evident at birth)

COMPLICATIONS

- Gait difficulties if left unattended

MANAGEMENT

Goals of Treatment

- Improve foot position

Metatarsus Varus

Usually requires no treatment if the condition is mild. Reassure the parents or caregiver and follow up closely. *See "Referral" in the "In-Toeing" section.*

Tibial Torsion

- Discuss with a physician
- Advise change in sleeping position

Increased Femoral Anteversion

- Change sitting position to tailor position
- Most children require no other intervention

Monitoring and Follow-Up

Monitor gait every 3 or 4 months.

Referral

- *Metatarsus varus:* Refer to a physician if the condition persists for more than 3 months or if there is a non-flexible deformity at birth.
- *Tibial torsion:* Refer to a physician. May require orthopedic consult

CONGENITAL DISLOCATION OF HIP (DEVELOPMENTAL DYSPLASIA OF THE HIP [DDH])

DEFINITION

Failure of femoral head to rest in acetabulum of pelvis (Hip Joint figure). There are three presentations: hip may be dislocated, dislocatable or subluxated.

Hip Joint

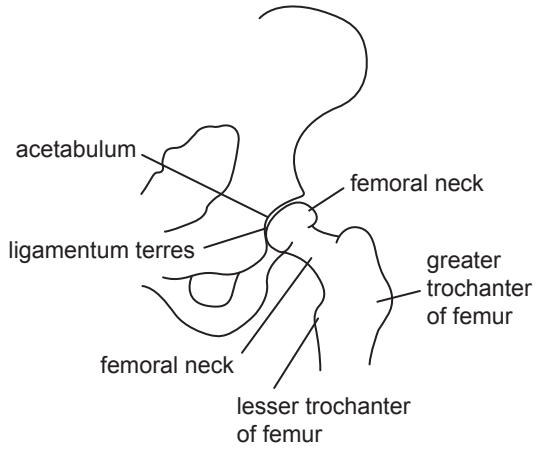

A check for congenital problems of the hip is part of routine neonatal screening. This condition is best diagnosed before the child begins walking. *See the "Musculoskeletal System" section under "Physical Examination of the Newborn" in Chapter 1, "Pediatric Health Assessment."*

CAUSES

- Congenital
- If the condition goes undetected, the use of tikanagans (cradle boards) or other means of swaddling may exacerbate the findings
- Breech birth

HISTORY

- If diagnosed after the child is walking, presents as a limp with or without pain

PHYSICAL FINDINGS

Inspection of the Newborn

- Asymmetric fat folds in thigh
- Extra skin folds on involved side

Inspection of the Older Child

- Legs unequal in length
- Limp
- Trendelenburg sign: lurching toward affected side

Palpation

- Examine child in supine position (on back)
- With thighs flexed, should be able to abduct to 90° in each hip; diagnosis should be suspected if abduction is limited to 60° to 70°

Ortolani-Barlow hip examination for screening newborns:

- Place middle fingers over greater trochanters (outer upper legs)
- Position thumbs on medial sides of knees
- Abduct the thigh to 90° by applying lateral pressure with thumb, push forward with middle fingers
- Move knee medially and then replace knee in starting position, push backward
- If there is a "clunk," the hip may be dislocatable
- If there is a "click," the hip may be subluxable

DIFFERENTIAL DIAGNOSIS

- Congenital short femur
- Synovial click
- Congenital adduction contraction
- Fixed dislocation in arthrogryposis

COMPLICATIONS

- Long-term disturbance of the gait if left undiagnosed and untreated
- Osteoarthritis

MANAGEMENT

Goals of Treatment

- Develop improved or normal femoral insertion into acetabulum
- Normalize gait

Nonpharmacologic Interventions

Early detection is important. Hence, the hip exam is an essential part of newborn screening. In addition, infants should be screened several times by nurse and physician during the first year of life, as the problem may not be evident at birth.

Educate community about potential treatments, such as decreased or partial use of tikanagan.

Definitive treatments:

- Splint (for example, Pavlik harness for children from birth to 8 months of age) (available at:http://orthopedics.about.com/od/pediatrichipinjuries/g/pavlik.htm).
- Casting
- Surgery
- Double diapering

Referral

Refer child as soon as possible for assessment by a physician.

LIMP

Gait abnormality.

This complaint should always be taken seriously. A limp may arise from problems in joints, bones, ligaments or soft tissues. In diagnosing a limp, it is difficult to distinguish bone pain from muscle and joint pain. Younger children (toddlers) may refuse to bear weight. Severe illness involving bone, joint or muscle may present as a limp. Pain may not be localized to the site of pathology.

CAUSES

Joint

Infection:

- Bacterial (septic arthritis)
- Viral

Inflammatory:

- Juvenile rheumatoid arthritis or rheumatic fever
- Reactive synovitis

Trauma:

- Congenital hip dysplasia
- Slipped capital femoral epiphysis (available at: http://emedicine.medscape.com/article/91596-overview)
- Legg-Calvé-Perthes disease

Bone

- Trauma
- Fracture
- Osteomyelitis
- Tumour (primary bone, neuroblastoma, leukemia)
- Leg length discrepancy
- Osgood-Schlatter disease

Muscle

- Sprains
- Strains
- Inflammatory process

Ligaments and Skin (Soft Tissue)

- Trauma
- Infection (cellulitis)
- Post-immunization

Limp may develop with spinal or abdominal involvement or injury.

HISTORY

- Trauma
- Fever
- Viral URTI in preceding week
- Pain
- Inability to bear weight
- Decreased mobility

PHYSICAL FINDINGS

Look for:

- Heat
- Swelling
- Redness
- Pain on movement
- Decrease in ability to bear weight
- Decrease in active and passive range of motion

Perform abdominal and general examinations if the cause is not evident on limb examination (for example, incarcerated inguinal hernia may present as a limp).

DIFFERENTIAL DIAGNOSIS

See "Causes".

COMPLICATIONS

Depends on the cause of the limp.

DIAGNOSTIC TESTS

– None

MANAGEMENT

Goals of Treatment

– Relieve pain, inflammation and fever (if present)
– Eradicate infection with appropriate antibiotics (if present)
– Treat underlying cause
– Maintain a high index of concern about possible pathology

Appropriate Consultation

Consult a physician if you are unsure of the diagnosis or the symptoms are significant.

Nonpharmacologic Interventions

Immobilization may be required to rest the limb, reduce pain and prevent further damage.

Pharmacologic Interventions

Antipyretic and analgesic for fever and pain:

ibuprofen (Advil, Motrin):

Children 6 months to 12 years: 5–10 mg/kg PO q6-8h prn; maximum 40 mg/kg/day

Children > 12 years: 200–400 mg q6-8h prn

Use lowest effective dose, shortest treatment duration; give with food

Ibuprofen also has anti-inflammatory effects

or

acetaminophen (Tylenol):

Infants and children < 12 years: 10–15 mg/kg/dose, PO q4-6h prn

Children and adolescents ≥ 12 years: 325–650 mg q4-6h; maximum 4 g/day

Monitoring and Follow-Up

Depends on the diagnosis.

Referral

Refer to a physician or to hospital as indicated by severity of symptoms and possible diagnosis.

GROWING PAINS

An idiopathic symptom complex that affects 10% to 20% of school-aged children. Pain usually occurs in shins or thigh muscles. Joint pain is rare. The pain is intermittent, usually occurring at night, and lasts from 30 minutes to several hours.

CAUSES

Unknown, although probably related to over-exertion and fatigue. Emotional factors may also play a role.

HISTORY

– Usually non-articular
– Calves or thighs usually involved
– Deep aching, usually worse at night
– May waken the child at night
– May be relieved with massage, rubbing

PHYSICAL FINDINGS

No physical signs.

DIFFERENTIAL DIAGNOSIS

– Rule out more severe disease or pathology
– Acute infection or inflammation
– Trauma
– When distinguishing growing pains from other more serious conditions, refer to the *"Ontario Association of Pediatricians"* (available at: http://www.utoronto.ca/kids/growpain.html) for a brief overview of presenting symptoms to consider.

COMPLICATIONS

– None

MANAGEMENT

Goals of Treatment

– Relieve pain
– Recover from fatigue

Nonpharmacologic Interventions

– Reassure child and family

Client Education

- Explain course of the condition and prognosis
- Counsel parents or caregiver about appropriate home management with rest, massage and analgesia
- Advise that heating pad or moist hot packs prn may help

Pharmacologic Interventions

Analgesic for pain (for children > 6 years old):

acetaminophen (Tylenol), 325 mg, 1–2 tabs PO q6h prn

or

ibuprofen (Motrin), 5–10 mg/kg per dose, q6-8h prn; maximum 40 mg/kg/day

Monitoring and Follow-Up

Reassess the child if attacks become more frequent or increase in severity.

Referral

Referral to a physician is not usually needed, unless the diagnosis is unclear or incorrect, or the symptoms are worsening.

OSGOOD-SCHLATTER DISEASE

Degeneration of the tibial tubercle at the insertion site of the quadriceps ligament. It is associated with rapid growth spurt and overuse in which repetitive microtrauma causes partial avulsion of the tibial tubercle at the insertion of the quadricep ligament and the patellar tendon.[4] May affect one or both knees.[5]

RISK FACTORS

- Male gender
- Active in sports (for example, football, soccer)
- Rapid growth spurt
- Most common in children aged 11–18 years[7]

CAUSES

- Activity (for example, sports and running), which causes microtrauma

HISTORY AND PHYSICAL FINDINGS

- Knee pain around the tibial tuberosity
- Soft tissue swelling
- Tenderness and prominence of the tibial tubercle
- Symptoms increase with activity (for example, running, jumping, going up and down stairs, kneeling) and are relieved by rest

DIFFERENTIAL DIAGNOSIS

- Patellar tendinitis
- Knee sprain
- Ligamentous strain
- Patellar femoral syndrome
- Osteomyelitis
- Osteosarcoma

COMPLICATIONS

- Detachment of cartilage fragments from the tibial tuberosity
- Decrease in capacity for physical activity

DIAGNOSTIC TESTS

- None

MANAGEMENT

Goals of Treatment

- Relieve pain and inflammation

Nonpharmacologic Interventions

- Reassure child and parents or caregiver as to the benign cause and favourable prognosis
- Rest the limb
- Application of ice or heat
- Massage[6]
- Decrease activities that aggravate symptoms
- Counsel parents or caregiver about appropriate use of medications

Pharmacologic Interventions

Analgesic for fever and pain:

ibuprofen (Advil, Motrin):

Children < 12 years: 5–10 mg/kg PO q6-8h prn; maximum 40 mg/kg/day

Children > 12 years: 200–400 mg q6-8h prn

Use lowest effective dose, shortest treatment duration; give with food

Ibuprofen also has anti-inflammatory effects

or

acetaminophen (Tylenol):

Children < 12 years: 10–15 mg/kg per dose, PO q4-6h prn

Children ≥ 12 years: 325–650 mg q4-6h; maximum 4 g/day

Monitoring and Follow-Up

Follow up in 1–2 weeks. The condition is usually self-limiting and resolves over several months.

Referral

Refer to a physician for evaluation if symptoms do not improve with conservative measures in 5–6 weeks. The condition may become chronic, with persistent tenderness, swelling and formation of ossicles, which may need surgical removal.

PATELLAR FEMORAL SYNDROME

Inflammation of cartilage and bone involving the patella, resulting in knee pain and swelling. It is considered an overuse syndrome not involving avascular necrosis or an inflammatory process, and as such it develops over a period of time.

Usually unilateral, but sometimes bilateral. Onset during adolescence.

Most of those affected show a mild degree of patellar femoral misalignment, which, with activity, causes instability of the patella and gradual destruction of the patellar cartilage.

RISK FACTORS

- Female gender
- Hypermobile joints
- Physical activity

CAUSES

Soft Tissue

- Prepatellar bursitis
- Patellar tendinitis
- Meniscal tear

Articular

- Chondromalacia patellae
- Patellar osteoarthritis
- Osteochondritis dissecans of the knee
- Chondral fracture

Functional

- Patellar instability
- Synovium caught between patella and femur

Referred Pain

- Back, hip or ankle pain

Mechanism

- Overuse syndrome in athletes
- Sports involving running, jumping, or quick stops and turns (pivots)
- Contact sports
- Direct impact to patella
- Degeneration of patella
- Chondromalacia patellae
- Patellar osteoarthritis
- Anatomic variation, such as increased angle between femur and tibia (Q-angle; note that females more often have larger Q-angle) or shallow outer patellofemoral groove (patella prone to sublux or dislocate laterally)

HISTORY

- Acute or chronic anterior knee pain and pain on underside of patella
- Gradually progressive, general aching or grating pain
- Sensation of the knee “giving out” and instability (reflex response to pain); child is unable to keep knee in flexed position for any length of time
- Grinding, popping or clicking sound on knee flexion
- Pain exacerbated with extended sitting and activities involving knee flexion such as running climbing or descending stairs[7]

PHYSICAL FINDINGS

- No knee effusion
- No decrease in range of motion of affected knee
- Tenderness of undersurface of medial or lateral patella
- Grinding, popping or clicking sound on knee flexion, detected on manipulation of patella
- Positive patellar inhibition test: child refuses to actively extend knee when patella is compressed against the femoral condyles; patella is displaced with knee extension
- Chronic pain may result in disuse atrophy of the quadriceps
- Crepitation when determining range of motion of knee
- Q-angle increased
- Abnormal patellar alignment

Apprehension Sign

- Hold patella as child lies with knee in extension
- Ask child to tense quadriceps muscle
- Positive result: child experiences pain
- Child may refuse to do the test in anticipation of pain

DIFFERENTIAL DIAGNOSIS

- Knee sprain
- Ligamentous strain
- Osgood-Schlatter disease

COMPLICATIONS

- Interference with daily activities

DIAGNOSTIC TESTS

- None usually. MRI may be of some diagnostic value

MANAGEMENT

Goals of Treatment

- Relieve pain and inflammation

Nonpharmacologic Interventions

- Rest; child can continue most activity, but for a short period in the acute stage (1–2 weeks), activities that require flexion of the knee should be limited
- Ice packs prn
- Tensor bandage may provide some comfort (should be worn only while child is awake)

Exercises to Strengthen Quadriceps

- Isometric progressive resistance exercises
- Leg-sled press (45°)

Exercises to Stretch Lower Extremity

- Quadriceps stretches
- Hamstring stretches
- Iliotibial band stretches
- Ankle stretches
- Gastrocnemius muscle stretches
- Soleus muscle stretches

Pharmacologic Interventions

Ant-inflammatory agents (NSAIDs) for short course (1–2 weeks):

ibuprofen (Advil, Motrin), 200 mg, 1–2 tabs PO q6-8h

or

naproxen (Naprosyn), 125 mg, 1–2 tabs PO bid to tid

Monitoring and Follow-Up

Reassess every 1–2 weeks during the acute stage. Ascertain adherence to exercise program, and provide support and encouragement.

Surgical arthroscopy may be needed (in 5% to 10% of cases) to remove bony or cartilaginous fragments or to shave the underside of the patella.

Referral

Refer to a physician for assessment if there is no improvement with conservative management after 6–8 weeks.

EMERGENCY PROBLEMS OF THE MUSCULOSKELETAL SYSTEM

MUSCULOSKELETAL INJURY

Trauma to the musculoskeletal tissue may cause damage that ranges from minor (for example, sprain) to major (for example, fracture or dislocation). *See Table 1, "Symptoms of Musculoskeletal Injury" for comparative information on the common symptoms of musculoskeletal injury*.

Refer to the *Adult Musculoskeletal chapter* for the Ottawa Ankle rules *(see the section "Assessment of the Muskuloskeletal System)*. The guidelines aid in the decision to use radiography for patients with injuries to the ankle and have been validated for children.[8]

Table 1 – Symptoms of Musculoskeletal Injury

Symptom	Fracture	Dislocation	Sprain	Strain
Pain*	Severe	Moderate to severe	Mild to moderate	Mild to moderate
Swelling	Moderate to severe	Mild	Mild to severe	Mild to moderate
Bruising	Mild to severe	Mild to severe	Mild to severe	Mild to severe
Deformity	Variable	Marked	None	None
Function	Loss of function	Loss of function	Limited	Limited
Tenderness	Severe	Moderate to severe	Moderate	Moderate
Crepitus	Present	Absent	Absent	Absent

* Pain level should be used as a guideline as pain threshold may vary considerably in children

FRACTURES

A break in the continuity of the bone. Fractures in children exhibit unique patterns because of the relative compressibility of their bone, the increased fibrous strength of the periosteum and the presence of the growth plate.[9]

CAUSES

Trauma is the most common cause.

Occasionally, pre-existing pathologic conditions may predispose to fractures:

- Osteogenesis imperfecta
- Osteopenia, such as seen in children with cerebral palsy
- Bony cyst
- Malignant lesion
- Rickets
- Scurvy

In the case of a fracture in an infant or toddler, the possibility of abuse should be considered.

Types of Fractures

Broad classifications of fractures describe them as closed (simple) or open (compound) and by appearance. *See Table 2, "Types of Fractures" for a more detailed description of pediatric fractures.*[10]

Table 2 – Types of Fractures

Type of Fracture	
General Classifications	**Description**
Closed (simple)	Fracture that does not produce an open wound in the skin
Open (compound)	Presence of an external wound leading to the break in the bone
Complete	A fracture in which bone fragments separate completely
Incomplete	A fracture in which the bone fragments are still partially joined
Undisplaced	Fractured bone stays in alignment
Displaced	Fractured bone goes out of alignment
Classification by Appearance	
Linear	Fracture parallel to the axis of the bone
Transverse	Fracture at right angles of the axis of the bone
Oblique	An angulated fracture line
Spiral (Torsion)	Multiplanar and complex fracture line
Comminuted	Fracture involving three or more fragments
Avulsion	Indirect fracture caused by avulsion or pull of a ligament
Impacted	Fracture that occurs when one bone hits or impacts an adjacent bone
Torus*	A fracture where there is a localized expansion or torus of the cortex, with little or no displacement of the lower end of the bone
Segmented	Type of comminuted fracture in which a segment of bone is delineated by two fracture lines
Compression	Impact fracture that occurs in the vertebrae
Bending	Indirect fracture caused by bending of a limb
Greenstick*	Incomplete angulated fracture of a long bone
Other Types	
Intra-articular	Fracture line crosses the articular cartilage and enters the joint
Stress (Fatigue)	Repeated pressure or load on normal bone, sufficient to cause a fracture
Salter-Harris (Growth plate)**	Epiphyseal fracture that involves the growth plate
Pathological	Fracture due to weakness of the bone structure by a disease process

* Often seen in children

** See *Salter-Harris fracture*. (Available at: http://emedicine.medscape.com/article/412956-overview) This type of fracture should always be referred to orthopedic service.

Sources: Mathison DJ, Agrawal D. (2010) *General principles of fracture management: Fracture patterns and description in children.* Fracture classification section. In UptoDate; In collaboration (2003) *Dorland's Illustrated Medical Dictionary* 30th ed. p. 736-37; Hoyt SK, Selfridge-Thomas J. (2007). *Emergency Nursing Core Curriculum*. 6th ed. p. 908-12.

HISTORY

Usually a history of trauma, except if there is pre-existing bone pathology. The fracture site and type is usually linked to the description and mechanism of injury.

- Determine exact mechanism of injury
- Pain
- Swelling
- Loss of function
- Possible numbness distal to fracture site

In abuse cases, classic features of the history may not be present or may not fit the reported injury.

PHYSICAL FINDINGS

- Respiratory rate, heart rate and blood pressure increased (because of pain)
- If there is significant associated blood loss, blood pressure may drop
- In older children, fracture of tibia, femur or pelvis may be associated with traumatic shock
- Child is distressed because of pain
- Skin lacerations near a fracture site with or without protruding bones may be present if fracture is compound
- Bruising and swelling
- Range of motion decreased
- Visible deformity if displaced
- Affected part may be pale if blood flow to the area is compromised
- Limb cool, pulses absent and sensation decreased if blood supply has been compromised, constituting an acute emergency
- Check temperature of area and presence of pulses distal to site of injury
- Test sensory function (to sharp and dull stimuli) distal to site of injury
- Affected area extremely tender
- If bones are displaced, crepitations may be felt

DIFFERENTIAL DIAGNOSIS

- Severe sprain
- Severe contusion
- Dislocation

COMPLICATIONS

Immediate (within First Few Hours)

- Hypovolemia from blood loss
- Shock
- Damage to arteries, neurovascular bundle and surrounding soft tissues

Early (within First Few Weeks)

- Wound infection
- Fat embolism
- Respiratory distress syndrome
- Chest infection
- Disseminated intravascular coagulopathy
- Osteomyelitis (if fracture is compound)
- Malunion and compartment syndrome may result from improper casting

Late (Months or Years Later)

- Contracture
- Delayed or malunion
- Osteoarthritis of adjacent or distant joints
- Aseptic necrosis
- Traumatic chondromalacia
- Reflex sympathetic dystrophy

DIAGNOSTIC TESTS

- X-ray, if available; if not, consult referring centre for definitive diagnosis
- If no fracture is seen on x-ray, but there is bony tenderness, it is prudent to treat as a fracture
- Growth plate fractures often appear normal on x-ray

MANAGEMENT

Most bones join in 4–6 weeks; lower-limb bones may take longer, and some greenstick fractures in children may take less time.

Goals of Treatment

- Stabilize fracture
- Relieve pain
- Prevent or manage complications
- Prevent or manage infection

Appropriate Consultation

Consult physician for all suspected or confirmed fractures.

Adjuvant Therapy

If there is a history of or clinical findings indicating significant trauma, and for all major fractures (for example, femur, pelvis, hip):

– Start intravenous (IV) therapy with normal saline and run at a rate sufficient to maintain hydration, unless hypotension is present

If hypotensive, treat for shock:

– Start oxygen using a non-rebreather mask; titrate to keep oxygen saturation > 97%
– Start 2 large-bore IVs with normal saline (or Ringer's lactate) or establish intraosseous access if IV access cannot be established within 60–90 seconds; *see "Intraosseous Access" in Chapter 2, "Pediatric Procedures"*
– Deliver bolus of 20 mL/kg over 20 minutes
– Repeat bolus as necessary until there is a response

See also *"Shock" in Chapter 20, "General Emergencies and Major Trauma"*.

Nonpharmacologic Interventions

– If spinal injury is suspected, keep child recumbent and use backboard with neck brace for transport
– Immobilize fracture site with a splint extending across joint, above and below site of injury
– Use a back slab cast or sling (for upper extremities) as appropriate
– For compound fracture, wrap skin wound with sterile dressing and protect by splinting
– Do not cast a fracture
– Do not attempt to reduce a displaced fracture
– For child with displaced fracture, give nothing by mouth, as surgery may be needed

Pharmacologic Interventions

Analgesic for mild to moderate pain:

ibuprofen (Advil, Motrin):

Children 6 months to 12 years: 5–10 mg/kg PO q6-8h prn; maximum 40 mg/kg/day

Children > 12 years: 200–400 mg q6-8h prn

Use lowest effective dose, shortest treatment duration; give with food

Ibuprofen also has anti-inflammatory effects

or

acetaminophen (Tylenol):

Infants and children < 12 years:
10–15 mg/kg per dose, PO q4-6h prn

Children and adolescents ≥ 12 years:
325–650 mg q4-6h; maximum 4 g/day

Narcotic analgesia may be necessary for more severe pain. Consult a physician before using narcotic analgesics.

Morphine:[12]

Oral : 0.2–0.5 mg/kg/dose PO q4-6h prn

I.M/I.V/S.C: 0.05–0.2 mg/kg/dose q2-4h prn

Maximum recommended injectable dose:

Infants: 2 mg/dose

Children 1–6 years: 4 mg/dose

Children 7–12 years: 8 mg /dose

Adolescents: 15 mg/dose

Note: Monitor closely for respiratory depression, especially in infants LESS THAN 3 months old because they are more susceptible.

Antibiotics are necessary if the fracture is compound. Consultation with a physician is required. IV or IM antibiotics are to be given only on the advice of a physician.

cefazolin (Ancef), 25–100 mg/kg/day IV (maximum 6 g/day), divided q6-8h

or

cefuroxime (Zinacef), 75–150 mg/kg/day IV (maximum 6 g/day), divided q8h

Tetanus toxoid should be given if indicated. Refer to *"Canadian Immunization Guide"* (Health Canada), 7th edition, 2006, for recommendations (available at: http://www.phac-aspc.gc.ca/publicat/cig-gci/index-eng.php).

Monitoring and Follow-Up

Monitor ABCs (airway, breathing and circulation), vital signs, pain control and neurovascular status of area distal to the fracture site while awaiting transfer to hospital.

After emergency treatment, take the opportunity to follow up with the child and parents or caregiver to offer guidance about accident prevention.

Referral

Medevac.

DISLOCATION OF A MAJOR JOINT

Displacement of a bone from normal anatomic insertion or attachment.

CAUSES

– Trauma is the most common cause

SPECIFIC CHILDHOOD ISSUES

Dislocations and fractures in infants and toddlers should be examined with consideration of the possibility of an abusive situation. Warning flags to consider:[11]

– Fracture in an infant younger than 1 year
– Spiral fractures
– Unwitnessed or unexplained injury
– Fractures in various healing stages
– History of other fractures
– Fracture that does not fit the stated mechanism of injury
– *Refer to Chapter 5, "Child Maltreatment" for assessment and management of potential maltreatment*

Pulled elbow (nursemaid's elbow) or subluxation of the radial head, is common in toddlers. It is caused by a sudden pull or jerk (trauma), during which the radial head is pulled out of the attached ligament (subluxation). Dislocation of the knees, ankles and elbows are true emergencies because of the potential for neurovascular problems.

HISTORY

– Associated trauma consistent with pattern of injury
– If history is not consistent with injury, consider the possibility of abuse
– Pain, often aggravated by movement
– Loss of function

PHYSICAL FINDINGS

– Tachycardia and tachypnea (related to pain)
– Swelling (mild)
– Bruising (mild to severe)
– Marked deformity of affected joint
– Tenderness (moderate to severe)
– Assess neurovascular status of affected limb

DIFFERENTIAL DIAGNOSIS

– Fracture
– Soft-tissue injury

COMPLICATIONS

– Vascular or nerve damage

MANAGEMENT

Goals of Treatment

– Relieve pain
– Realign dislocated or fractured bones

Appropriate Consultation

Consult a physician. If a larger joint is dislocated, medevac will probably be needed.

Nonpharmacologic Interventions

– Give nothing by mouth, in case surgery is required
– Immobilize the site with a back slab cast or sling (for upper extremities), as appropriate

Pharmacologic Interventions

Analgesic for mild to moderate pain:

ibuprofen (Advil, Motrin):

Children 6 months to 12 years:
5–10 mg/kg PO q6-8h prn;
maximum 40 mg/kg/day

Children > 12 years: 200–400 mg q6-8h prn

Use lowest effective dose, shortest treatment duration; give with food

Ibuprofen also has anti-inflammatory effects

or

acetaminophen (Tylenol):

Infants and children < 12 years:
10–15 mg/kg per dose, PO q4-6h prn

Children and adolescents ≥ 12 years:
325–650 mg q4-6h; maximum 4 g/day

Narcotic analgesics may be necessary for severe pain. Consult a physician before using narcotic analgesics.

Morphine:[12]

Oral : 0.2–0.5 mg/kg/dose PO q4-6h prn

I.M/I.V/S.C: 0.05–0.2 mg/kg/dose q2-4h prn

Maximum recommended injectable dose:

Infants: 2 mg/dose

Children 1–6 years: 4 mg/dose

Children 7–12 years: 8 mg /dose

Adolescents: 15 mg/dose

Note: Monitor closely for respiratory depression, especially in infants LESS THAN 3 months old because they are more susceptible.

Monitoring and Follow-Up

Monitor for control of pain and to determine the neurovascular status of the involved limb.

Referral

Medevac for orthopedic consult and definitive treatment.

DISLOCATION OF A SMALLER JOINT

The physician may advise that small joints (for example, fingers) be realigned by gentle traction. Once relocated, immobilize the joint to allow for healing. The duration of immobilization will depend on the joint involved and should be determined by a physician. Fingers should never be immobilized for more than 3 or 4 days.

SOURCES

Internet addresses are valid as of February 2012.

BOOKS AND MONOGRAPHS

Bickley LS. *Bates' guide to physical examination and history taking.* 7th ed. Baltimore, MD: Lippincott Williams & Wilkins; 1999.

Burns CE, Dunn AM, Brady MA, Starr NB, Blosser CG. *Pediatric primary care*. 4th ed. Saunders Elsevier; 2009.

Cheng A, Williams B, Sivarajan B (Editors). *The Hospital for Sick Children handbook of pediatrics*. 10th ed. Toronto, ON: Elsevier Canada; 2003.

Cohen J, Powderly WG. *Infectious diseases.* 2nd ed. New York, NY: Elsevier; 2004.

Colman R, Somogyi R (Editors-in-chief). *Toronto Notes – MCCQE 2008 review notes.* 24th ed. Toronto, ON: University of Toronto, Faculty of Medicine; 2008.

Ferri FF. *Ferri's clinical advisor: Instant diagnosis and treatment.* St. Louis, MO: Mosby; 2004.

Gray J (Editor-in-chief). *Therapeutic choices.* 5th ed. Ottawa, ON: Canadian Pharmacists Association; 2007.

Health Canada. *Canadian immunization guide.* 7th ed. Ottawa, ON: Health Canada; 2006.

Hoyt SK, Selfridge-Thomas J. *Emergency nursing core curriculum.* 6th ed. Saunders Elsevier; 2007.

Jensen B, Regier L (Editors). *The Rx files.* 7th ed. Saskatoon, SK: 2008.

Repchinsky C (Editor-in-chief). *Compendium of pharmaceuticals and specialties: the Canadian reference for health professionals.* Ottawa, ON: Canadian Pharmacists Association; 2007.

Rosser W, Pennie R, Pilla N, and the Anti-infective Review Panel (Canadian). *Anti-infective guidelines for community-acquired infections.* Toronto, ON: MUMS Guidelines Clearing House; 2005.

Rudolph CD, et al. *Rudolph's pediatrics*. 21st ed. McGraw-Hill; 2003.

Schilling JA. *Nurse's quick check diseases.* 2nd ed. Wolters Kluwer Lippincott Williams & Wilkins; 2009. p. 454.

Uphold CR, Graham MV. *Clinical guidelines in child health*. 4th ed. Gainesville, FL: Barmarrae Books; 2003.

INTERNET GUIDELINES / ARTICLES / DOCUMENTS

Bhatia MM, Ertl JP, Kovacs G. (2006, April). *Osgood-Schlatter disease: Treatment & medication.* Available at: http://emedicine.medscape.com/article/1993268-treatment

McCarthy JJ. (2008, June). *Developmental dysplasia of the hip.* Available at: http://emedicine.medscape.com/article/1248135-overview

McCarthy JJ. (2008, June). *Developmental dysplasia of the hip: Treatment.* Available at: http://emedicine.medscape.com/article/1248135-treatment

Moses S. (2010, March). *Benign nocturnal limb pains of childhood.* Available at: http://www.fpnotebook.com/Rheum/Peds/BngnNctrnlLmbPnsOfChldhd.htm

Moses S. (2010, March). *Congenital hip dislocation.* Available at: http://www.fpnotebook.com/Ortho/Peds/CngntlHpDslctn.htm

Moses S. (2010, March). *Femoral anteversion.* Available at: http://www.fpnotebook.com/Ortho/Peds/FmrlAntvrsn.htm

Moses S. (2010, March). *In-toeing.* Available at: http://www.fpnotebook.com/Ortho/Peds/inTng.htm

Moses S. (2010, March). *Internal tibial torsion.* Available at: http://www.fpnotebook.com/Ortho/Peds/IntrnlTblTrsn.htm

Moses S. (2010, March). *Legge-Calve-Perthes*. Available at: http://www.fpnotebook.com/Ortho/Peds/LgClvPrths.htm

Moses S. (2010, March). *Metatarsus adductus.* Available at: http://www.fpnotebook.com/Ortho/Peds/MtrsAdcts.htm

Moses S. (2010, March). *Musculoskeletal pain in children: Red flags.* Available at: http://www.fpnotebook.com/Rheum/Sx/MsclskltlPnInChldrnRdFlgs.htm

Moses S. (2010, March). *Pediatric limp.* Available at: http://www.fpnotebook.com/Rheum/Sx/PdtrcLmp.htm

Wai Lin B, Schraga ED, Stevens KJ. (2008, June). *Pediatrics, Limp: Differential diagnosis & workup.* Available at: http://emedicine.medscape.com/article/802506-diagnosis

Wai Lin B, Schraga ED, Stevens KJ. (2008, June). *Pediatrics, Limp: Treatment & medication.* Available at: http://emedicine.medscape.com/article/802506-treatment

END NOTES

1 Burns CE, Dunn AM, Brady MA, Starr NB, Blosser CG. *Pediatric primary care*. 4th ed. Saunders Elsevier; 2009. p. 1004.

2 Schilling JA. *Nurse's quick check diseases.* 2nd ed. Wolters Kluwer Lippincott Williams & Wilkins; 2009. p. 454.

3 Burns CE, Dunn AM, Brady MA, Starr NB, Blosser CG. *Pediatric primary care*. 4th ed. Saunders Elsevier; 2009. p.1005.

4 Uphold CR, Graham MV. *Clinical guidelines in family practice.* 4th ed. Gainesville, FL: Barmarrae Books; 2003. p. 830.

5 Schilling JA. *Nurse's quick check diseases.* 2nd ed. Wolters Kluwer Lippincott Williams & Wilkins; 2009. p. 562.

6 Ipp M. *Growing pain.* Ontario Association of Pediatricians. Available at: http://www.utoronto.ca/kids/growpain.html

7 Uphold CR, Graham MV. *Clinical guidelines in family practice.* 4th ed. Gainesville, FL: Barmarrae Books; 2003. p. 831.

8 Plint AC, Bulloch B, Osmond MH, et al. Validation of the Ottawa Ankle Rules in children with ankle injuries. *Acad Emerg Med* 1999;Oct;6(10):1005-9. Available at: http://www.ncbi.nlm.nih.gov/pubmed/10530658

9 Mathison DJ, Agrawal D. (2010). *General principles of fracture management: Fracture patterns and description in children.* Introduction and Summary sections. Available by subscription: www.uptodate.com

10 Hoyt SK, Selfridge-Thomas J. *Emergency nursing core curriculum*. 6th ed. Saunders Elsevier; 2007. p. 908.

11 Hoyt SK, Selfridge-Thomas J. *Emergency nursing core curriculum*. 6th ed. Saunders Elsevier; 2007. p. 899.

12 *Morphine sulfate: Pediatric drug information*. (February 2012) UpToDate Online 19.3. Available at: www.uptodate.com